



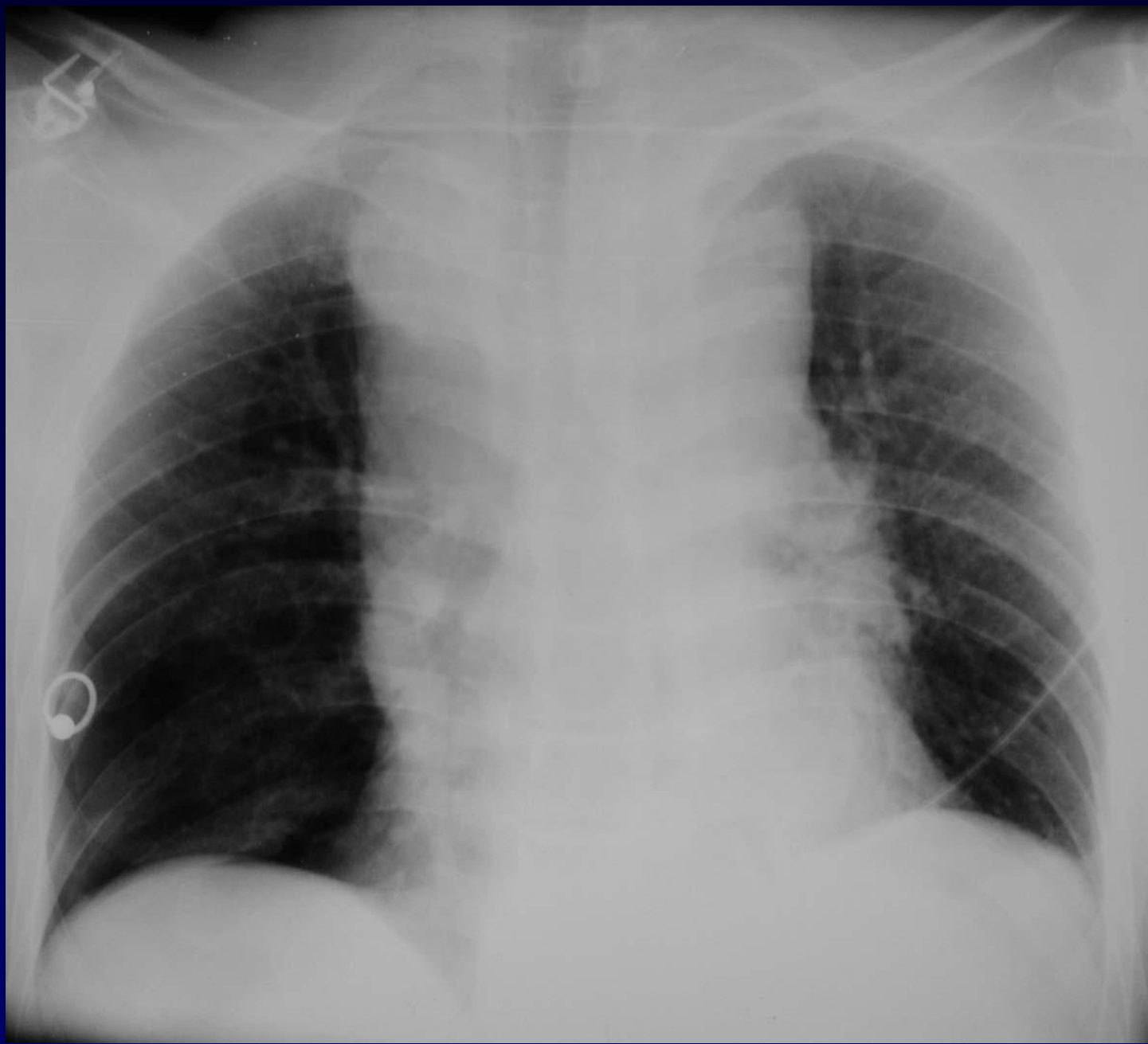
L. METGE

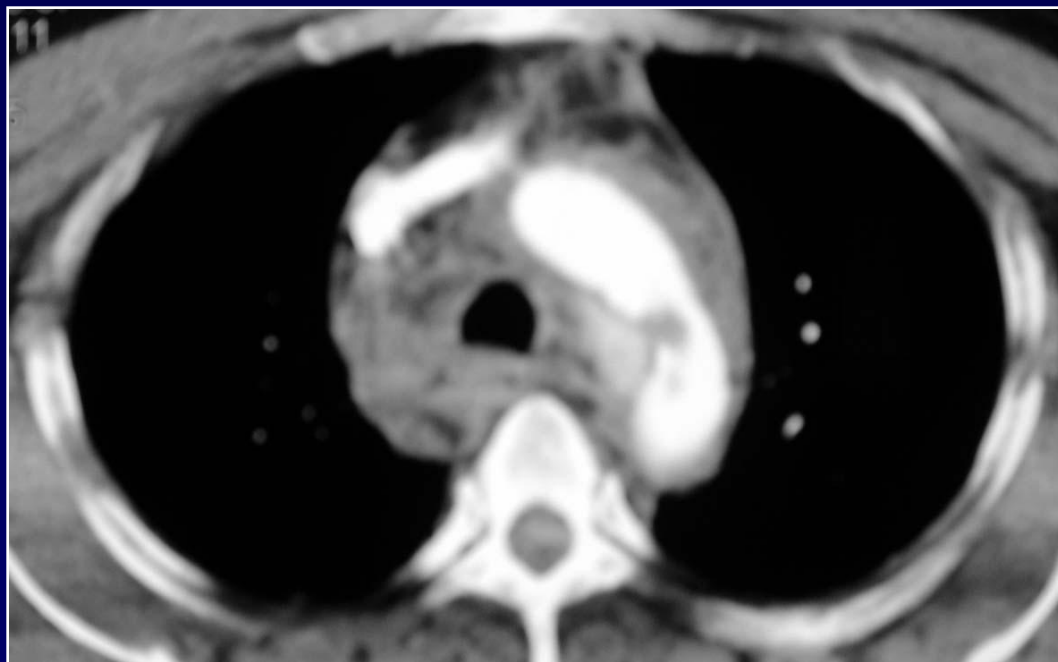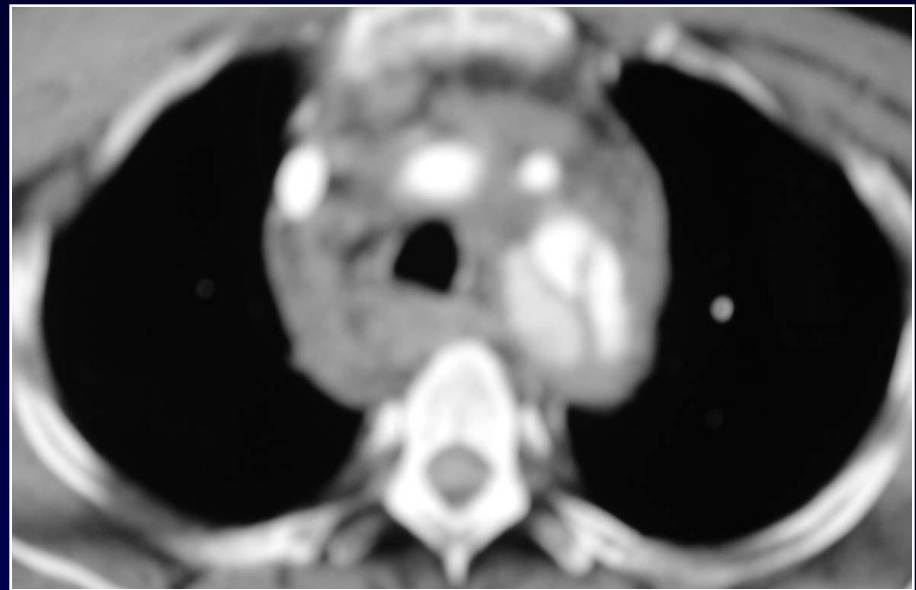
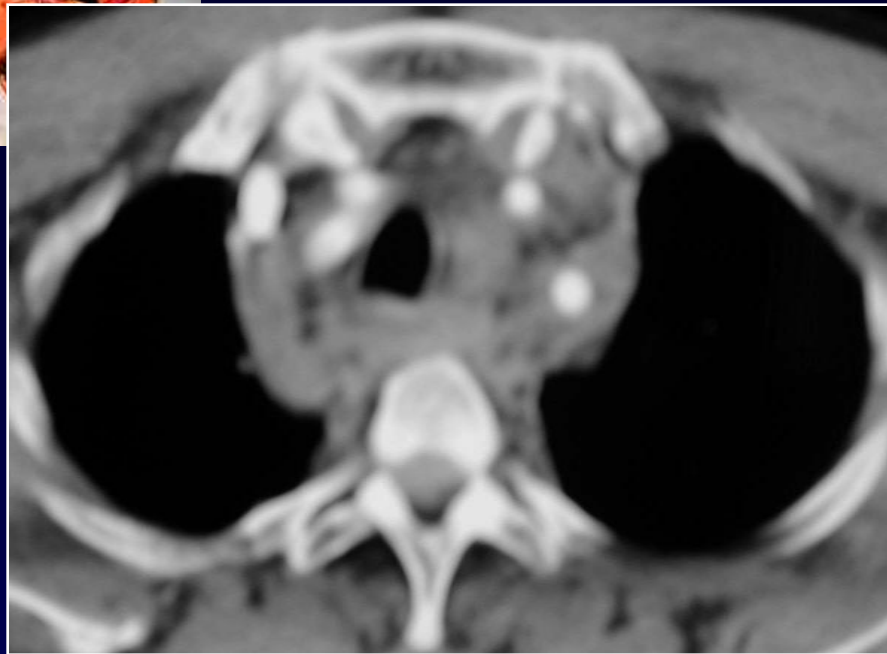Homme de 37 ans

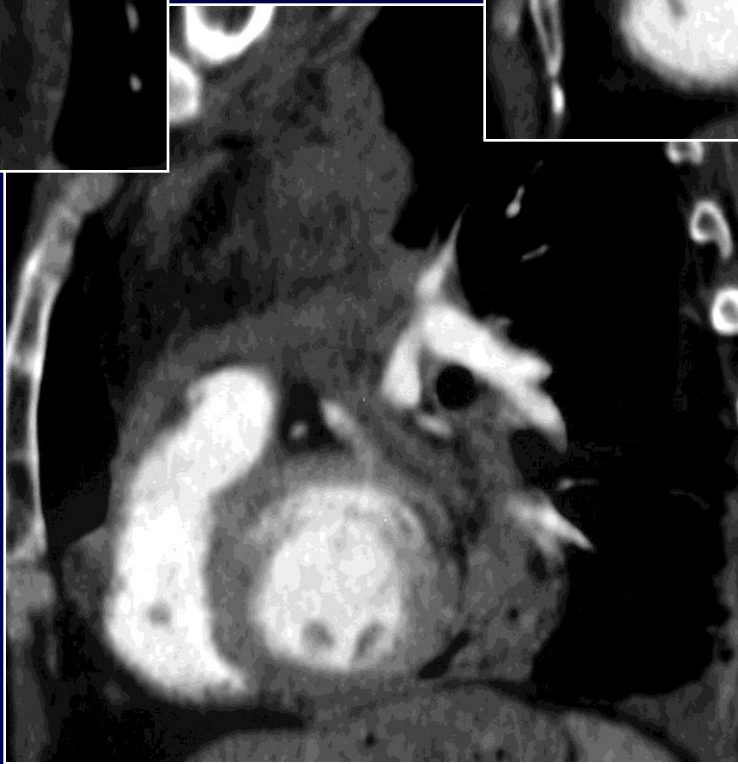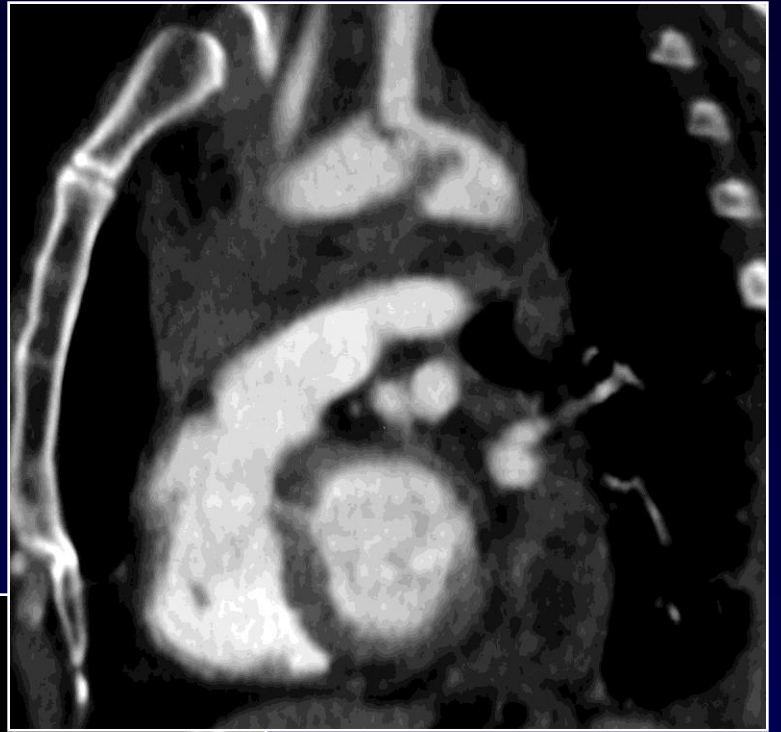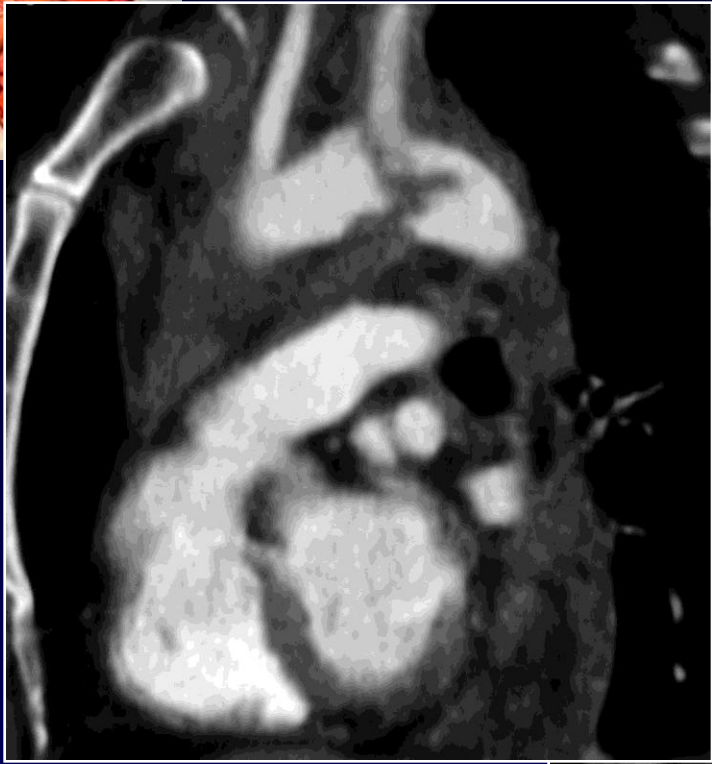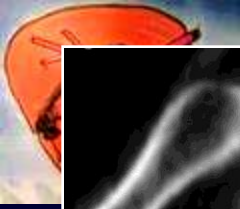Accident de la voie publique

Patient non ceinturé

collapsus









Diagnostic ?



Rupture traumatique de l'aorte